MODERN MEDICINE AND PRACTICE
https://inovatus.es/index.php/ejmmp

EUROPEAN JOURNAL OF MODERNMEDICINEAND PRACTICE
Vol. 4 No. 6 (Jun - 2024) EJMMP ISSN: 2795-921X

RESULTS OF MRI AND CT ASSESSMENT OF EPILEPSY SYMPTOMS IN PATIENTS WITH CEREBRAL PALSY

Artikova Mavluda Abdurakhmonovna
Bukhara State Institute named after Abu Ali ibn Sina, the Republic of Uzbekistan

Abstract: The article presents the results of an assessment of perfusion MRI and CT studies in cerebral palsy with epilepsy. Perfusion -weighted MRI and CT studies of the brain were carried out in 25 children with cerebral palsy and among 23 practically healthy children. The study of magnetic resonance images of the brain allowed us to determine quantitative (PN, MTT) and semi-quantitative (CBV, CBF) perfusion indicators. The gray matter of the brain has higher perfusion rates compared to the white matter of the brain.

Key words: Perfusion magnetic resonance imaging, cerebral blood flow velocity, cerebral blood flow volume, cerebral palsy, epilepsy.

Relevance . Epilepsy represents one of the most complex medical and social problems . The term “cerebral palsy” (CP) unites a group of syndromes with different clinical manifestations that arise as a result of underdevelopment of the brain and its damage at various stages of ontogenesis and are characterized by the inability to maintain a normal posture and perform voluntary movements [2,3]. The increasing prevalence of cerebral palsy (CP) in industrialized countries is the most important problem in pediatric neurology. The use of neuroimaging methods made it possible to clarify pathomorphological changes in the central nervous system in patients with cerebral palsy during life. The subject of discussion remains both the main reasons for the formation of hyperkinesis and morphological changes in the structure of the brain according to neuroimaging data .

neuroimaging methods such as magnetic resonance imaging (MRI) and computed tomography (CT) perfusion are of decisive importance for the diagnosis and prognosis of the severity of epilepsy in cerebral palsy [6,10,12]. Perfusion MRI provides additional information about the state of cerebral perfusion compared to structural neuroimaging methods . Perfusion MRI does not require the use of radioisotopes and does not use x-rays, which is critical in pediatric neuroradiology . Moreover, when used in combination with standard pulse sequences and spectroscopy, perfusion MRI provides additional information about the area of interest in the brain, which generally increases the accuracy and specificity of diagnosing epilepsy in children [4,9].

Currently, most studies of the central nervous system in children require the use of MR contrast agents, and if the MR tomograph software package contains an appropriate pulse sequence, the use of this method does not increase the cost of MRI and the total scanning time in general. Post-processing of perfusion images allows the construction of parametric images that provide useful information for characterizing tissue perfusion abnormalities.

Cerebral perfusion is assessed using the following parameters (Fig. 1):

- cerebral blood flow velocity (CMB, CerebralBloodFlow , CBF)
- cerebral blood flow volume (CBV, CerebralBloodVolume , CBV)
- mean transit time of the contrast agent (SVT, MeanTransitTime , MTT).

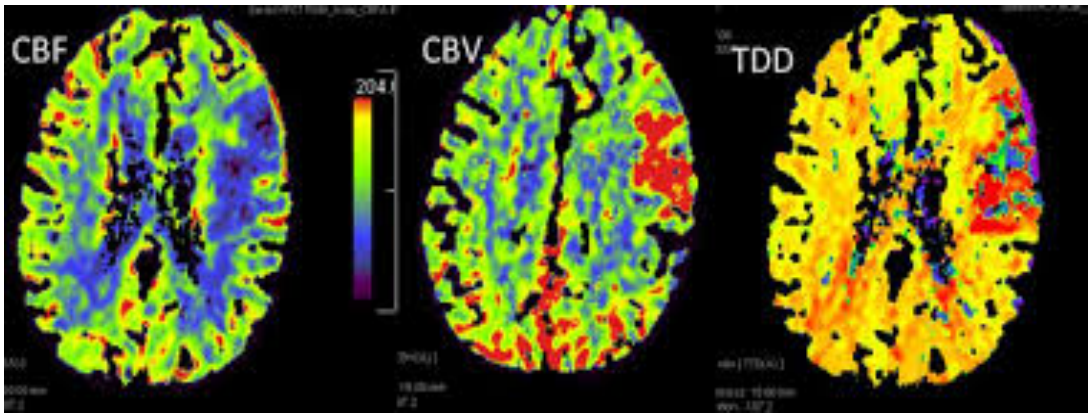

A B C.

Rice. 1. Cerebral perfusion parameters: a) cerebral blood flow velocity (CBF), b) cerebral blood flow volume (CBV), c) average transit time of the contrast agent (MTT) .

Cerebral blood flow velocity is the most significant indicator of brain perfusion, which is defined as the amount of blood passing through a unit volume of brain tissue over a certain time period and is measured in [ml blood / 100 g brain matter /min]. SMC normally ranges from 50 to 80 ml/100 g/min. Well -perfused areas of the brain, such as the cortex and basal ganglia, exhibit SMC levels 2–3 times higher than the white matter [7, 9].

The volume of cerebral blood flow is measured in ml/100 g of brain tissue and allows you to estimate the amount of blood per unit volume of brain tissue. Well - vascularized areas of brain tissue (cortex, basal ganglia) have a higher level of TMC than white matter . OMC is a functional parameter that depends on the diameter of the vessels when self-regulatory mechanisms are activated [8,12] . The most common measure of decreased cerebral perfusion is the mean contrast transit time (MCT), measured in seconds. There is a direct dependence of SVT on the level of intracranial pressure. Even minimal changes in intracranial pressure lead to an increase in SVT.

Thus, based on the above, **the purpose of the study is** was to study the diagnostic capabilities of perfusion MRI and CT studies in cerebral palsy with epilepsy.

Materials and methods : the research was based on the results of a survey of 25 children with symptomatic epilepsy in cerebral palsy and 23 healthy children aged 1 to 18 years. The patients were examined and treated at the clinical base of the Bukhara Regional Children's Psychoneurological Hospital and the Regional Children's Multidisciplinary Center for the period from 2023 to 2024. According to gender gradation, boys predominated in a ratio of 1.1:1. The onset of epileptic seizures was noted from birth to 2.5 years, the average age of onset was 5.6±0.16 months. The average duration of the disease was 3.87±0.38 years.

MRI studies were performed using standard technology (axial, frontal and sagittal projections). MRI tomography was performed on a Siemens device Concerto » 1.5T.

The purpose of this chapter was to study the diagnostic capabilities of perfusion MRI and CT studies in cerebral palsy with epilepsy. Perfusion -weighted MRI and CT studies of the brain were carried out in 25

children with cerebral palsy and among 23 practically healthy children. All children underwent a comprehensive clinical and instrumental examination, including non-contrast CT and perfusion CT, and perfusion MRI. During PCT, on the section with the largest zone of perfusion disturbances, the area of areas with altered perfusion parameters was measured. The study of magnetic resonance images of the brain allowed us to determine quantitative (PN, MTT) and semi-quantitative (CBV, CBF) perfusion indicators. When performing perfusion CT, we measured perfusion parameters: MBF, MOC and MTT. (Table 1).

Table 1 Changes in perfusion parameters of white and gray matter in cerebral palsy and in healthy children

Groups of examined children	Anatomical region	SMK, CBF ml/100g x min	OMK, CBV ml/100g	SVT, MTT sec
Healthy children (n=23)	White matter	25	4	4.8
	Gray matter	60	2	4
Cerebral palsy with epilepsy (n=25)	White matter	↘	↘	↘
	Gray matter	↓	↓	↘

The area of decreased cerebral blood flow volume (CBF) in the brain was 1475.73 mm2, decreased cerebral blood flow velocity of the CBF was 2591.14 mm2, and increased mean transit time of the contrast agent (MTT) was 2198.10 mm2. Our studies revealed a significant decrease in areas of reduced SMC to 1345.12 mm2; p=0.007), areas of change in TMC and MTT at this time remained without significant changes (1341.89 mm2; p=0.143 and 2054.67 mm2; p=0.688, respectively). Established using neuroimaging methods and perfusion studies of the changes state that the presence of areas of reversible changes in blood supply in the epileptic area in the first day after paroxysmal attacks, which correspond to areas of reduced SMB without disruption of the MBV and average contrast transit time. A decrease in perfusion disturbances in the area occurs due to the restoration of perfusion in this area, while perfusion insufficiency in the area of altered MTT and SMC remains unchanged (Fig. 2).

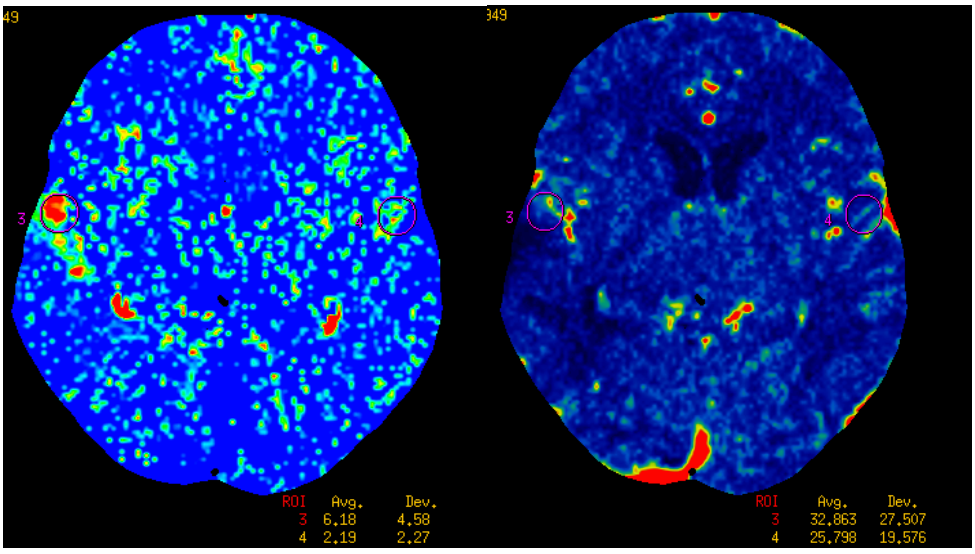

Rice. 2. Patient M., 12 years old, with symptomatic focal epilepsy without structural changes on MRI. CT perfusion: areas of decreased cerebral blood flow (CBF) and decreased mean contrast transit time (MTT).

Thus, in clinical practice, perfusion CT and MRI make it possible to determine not only areas of encephalomalacia , but also to establish the ratio of tissue viability in the structures of the white and gray

matter of the brain . The MTT formulation can be presented in this form with IOC and MK: MK = IOC/MTT. In various pathological conditions, including cerebral palsy, developmental anomalies, after neuroinfections complicated by paroxysmal conditions, this ratio is disrupted. When analyzing CT and MRI perfusion parameters, we used the following scales: MK - values from 0 to 120 ml/100 g/min; IOC - values from 0 to 8 ml/100 g; MTT - values from 0 to 10 s.

In modern neuroradiology, there are practically no studies devoted to the quantitative and qualitative assessment of MRI and CT brain perfusion parameters. In studies by other authors, the relative values of the decrease in blood flow parameters compared to the contralateral side of the brain have been established. This result may not always serve as a reliable indicator for assessing brain tissue, since hyperemia associated with activation of collateral blood flow may be observed in the contralateral side. During an examination of 23 healthy children (control group) who did not have paroxysmal attacks, whose brain examinations were carried out during other examinations. The following results were revealed: the average value of cerebral blood flow in the frontal lobe of the brain was 22.08±3.98 ml/100 g/min in the right hemisphere and 21.465±4.64 ml/100 g/min in the left hemisphere. Similar digital values were obtained in the temporal lobes on both sides: 20.54 ± 4.09 ml/100 g/min and 21.87 ± 4.04 ml/100 g/min, respectively. In the occipital lobes of the white matter, cerebral blood flow values were low: on the right 19.87 ± 3.20 ml/100 g/min and on the left 20.01 ± 3.70 ml/100 g/min.

Computed tomographic perfusion study parameters of cerebral blood flow of white matter were lower than normal values of perfusion of white matter of the brain than in the control group (26-36 ml/100 g/min).

The average value of this indicator in the thalamus was on average 53.34±7.26 ml/100 g/min in the right hemisphere and 54.83±7.84 ml/100 g/min in the left hemisphere. In general, the average values of cerebral blood flow of the white matter of the brain in the right hemisphere were 20.98 ± 4.45 ml/100 g/min , in the left hemisphere 20.97 ± 4.40 ml/100 g/min.

Digital perfusion parameters in the gray matter of the thalami fell within the normal limits of cerebral blood flow (50-70 ml/100 g/min). The research results we obtained are confirmed in the works of other foreign authors. According to a group of researchers, Bazilevich, S.N. , normal values of cerebral blood flow obtained from CT perfusion ranged from 15.9±4.1 ml/100 g/min (white matter of the brain) to 38.2±11.3 ml/100 g/min (gray matter of the brain brain).

The average values of cerebral blood flow in the white matter had the following parameters : In the right temporal region, SMB was 2.12 ± 0.39 ml/100 g and in the left temporal region 2.45 ± 0.41 ml/100 g. In the right frontal region 2.15 ± 0.44 ml/100 g and the left frontal region 1.97 ± 0.29 ml/100 g. In the occipital region on the right, the SMC of the white matter varied 2.13 ± 0.34 ml/100 g and on the left 2.35 ± 0, 54 ml/100 g.

According to our studies, the CT perfusion parameters are presented as follows : the average contrast transit time was 6.35±0.71 in the right frontal region and 5.56±0.67 in the left frontal region. MTT was 8.08±1.09 in the right temporal region and 8.05±0.54 in the left temporal region. In the parieto-occipital areas on both sides the average was 7.88±0.87.

The average transit time of contrast in the white matter of the brain was 7.09 ± 0.76 on the right side and 7.09 ± 0.53 on the left.

Digital values of MTT in the gray matter of the thalami: on the right 5.5±0.71, and 4.03±0.72 on the left. The average values of cerebral blood flow in the white matter were 2.14±0.53 ml/100 g; the parameters on the left were within the range of 2.01±0.45 ml/100 g. In the projection of the thalami, the values of cerebral blood flow were: 4.10±0.41 ml/100 g (right) and 4.25±0.48 ml/100 g (left).

After post- processing, we calculated the average contrast transit times in the gray and white matter of the

brain. Based on the data obtained, perfusion was assessed in children with cerebral palsy and in healthy children. The average values of MC, MOC and MTT were used as the norm for white and gray matter in the ±SD range. When assessing MRI perfusion parameters in color mapping mode, a brighter signal from the gray matter of the brain was clearly identified compared to the white matter. As a result of our research, we developed perfusion characteristics of the normal brain and identified the following signs: 1. Perfusion indicators were characterized by equal average contrast transit time and time to peak for both hemispheres of the brain in healthy children. 2. A clear demarcation was revealed between the gray and white matter of the brain. 3. There is a uniform and clear distribution of MR and CT perfusion indicators when performing color mapping.

Conclusion.

Thus, the results obtained in the study of children with cerebral palsy and healthy children (control group) allowed us to draw the following conclusions: In healthy children aged 1 to 13 years, there is no difference between perfusion indices (CBV , CBF , PBV) in boys and girls. The gray matter of the brain has higher perfusion rates compared to the white matter of the brain . Perfusion MRI and CT are characterized by high information content in assessing changes in brain tissue in cerebral palsy and other pathological conditions

The use of a complex of MRI and CT diagnostic techniques, including assessment of brain perfusion, in children with cerebral palsy has proven its feasibility. Brain perfusion characteristics (CBV , CBF , PBV , PS , PRSq) allow us to assess the prognosis and course of the disease. The speed of performing MR, CT perfusion and evaluation of results, the absence of contraindications, and high diagnostic information content are the undoubted advantages of functional neuroimaging methods .

List of used literature

1. Aicardi J. Nervous system disease in children / Trans. from English Protsenko T.S., Barashkova S.V., general editor. Skoromets A.A. - T.1. – M.: BINOM-Panfilov Publishing House, 2013. - 568 p.
2. Alikhanov A.A. Imaging of epileptogenic brain lesions in children. – M.: Vidar – M. – 2009. - 272 p.
3. Aminova D.A., Sadykova G.K. Genealogical characteristics of children with epileptic encephalopathy and symptomatic epilepsy // Neurology. -2012. - No. 3-4 (55-56). - P.183.
4. Artykova M.A. Possibilities of magnetic resonance spectroscopy in the diagnosis of epilepsy in patients with cerebral palsy. Medical Journal of Uzbekistan. – Tashkent, 2018.-No.1.- P.43-48.
5. Batysheva T.T., Tripilets S.V., Badalyan O.L. Cerebral palsy and epilepsy. Modern approaches to treatment. Method.recomm. - M., 2016. - No. 27. - 24 s.
6. Evstigneev V.V., Kisten O.V., Bulaev I.V., Sakovich R.A. Experience in the use of diffusion tensor magnetic resonance imaging in the morphological diagnosis of epilepsy. Neurology and neurosurgery. Eastern Europe. 2012; 4 (16): 97.
7. Efimtsev A.Yu. Possibilities of diffusion tensor magnetic resonance imaging in assessing damage to pathways in non-tumor diseases of the brain: abstract . diss . Ph.D. med.sc. St. Petersburg 2011.
8. Totolyan , A.A. Complex clinical, electroencephalographic and neuroimaging diagnostics of locally caused epilepsy / L.V. Lipatova, A.V. Vasilenko, D.E. Dyskin , N.A. Sivakova, A.A. Totolyan et al . // Russian Neurosurgical Journal named after. A.L. Polenova . – 2013. – T.5, special. release. – P.298.
9. Artikova MA Morphological changes in children with cerebral palsy with symptomatic epilepsy. European science review magazine . - Austria , 2016 . - No. 7-8. – R. 49-51.
10. Kisten, O.V. (2012) Experience of diffusion tensor magnetic resonance imaging in the morphological diagnosis of epilepsy. Neurology and Neurosurgery. 4: 95-97.

11. Le Bihan D, (2012). MR imaging of intravoxel incoherent motions: application to diffusion and perfusion in neurological disorders. Radiology, 161: 401-407.
12. Sakakibara T., Nakagawa E., Saito Y., Sakuma H., Komaki H., Sugai K., Sasaki M., Kurahashi H., Hirose S. Hemiconvulsion -hemiplegia syndrome in a patient with severe myoclonic epilepsy in infancy // Epilepsy . - 2009. - V. 1.
13. Артыкова М. А., Набиева Н. А. Клинико-анамнестические факторы риска развития симптоматической эпилепсии при детском церебральном параличе //журнал неврологии и нейрохирургических исследований. – 2021. – №. SPECIAL 1.
14. Artikova M. A., Djurayeva D. N. Clinical and anamnestic risk factors for the development of symptomatic epilepsy in infantile cerebral palsy //Web of Scientist: International Scientific Research Journal. – 2021. – Т. 2. – №. 10. – С. 29-34.
15. Артыкова М. А. Клинико-Неврологические Особенности Больных, Перенесших Коронавирусную Инфекцию (Covid-19) //Central asian journal of medical and natural sciences. – 2021. – С. 338-342.
16. Abdurakhmanovna A. M., Abdurakhimovna N. N. Content and distribution of haptoglobin phenotypes in children with cerebral palsy complicated by symptomatic epilepsy. – 2021.
17. Artykova M. A., Nabieva N. A. Radiated semiotics of perfusion brain disorders in epilepsy in children cerebral paralysis. – 2020.
18. Artikova M. A., Nabiyeva N. A. Complicated symptomatic epilepsy, content and distribution of haptoglobin phenotypes in children with cerebral palsy //Turkish Journal of Physiotherapy and Rehabilitation. – Т. 32. – С. 3.